

## Chapter 2

### Arterial Cannulation

*Dr Shefali Chaudhari  
Dr Cyprian Mendonca*

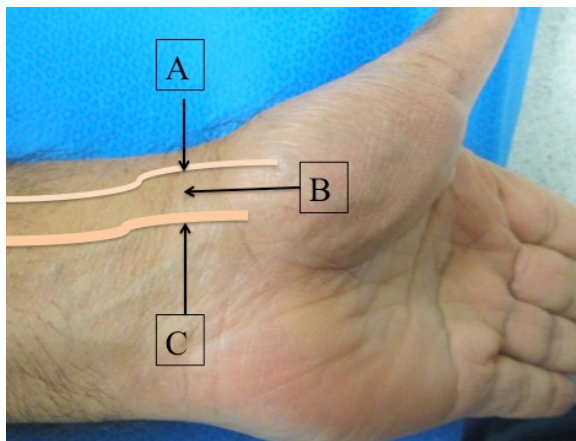
Insertion of a cannula into an artery enables to monitor beat by beat values of pulse rate, systolic, diastolic and mean arterial blood pressure accurately. Presence of cannula in artery also enables to take frequent blood samples for analysing blood gases and electrolytes in intensive care and during anaesthetic management of high risk patients.

#### Applied anatomy

The radial artery lies between the brachioradialis and flexor carpi radialis tendons. The tendons of these muscles act as landmark to palpate the artery.

Beyond the wrist, artery gives a branch that contributes to superficial palmar arch. The main arterial branch continues over the scaphoid and beneath the extensor and abductor tendons of thumb to pass between first and second metacarpal bones to contribute to the deep palmar arch.

The artery should be punctured as distal as possible but atleast 1 cm proximal to the styloid process.



*Figure 1: Anatomical land marks for radial artery cannulation; brachioradialis tendon (A), site of radial artery puncture (B) and flexor carpi radialis tendon (C)*

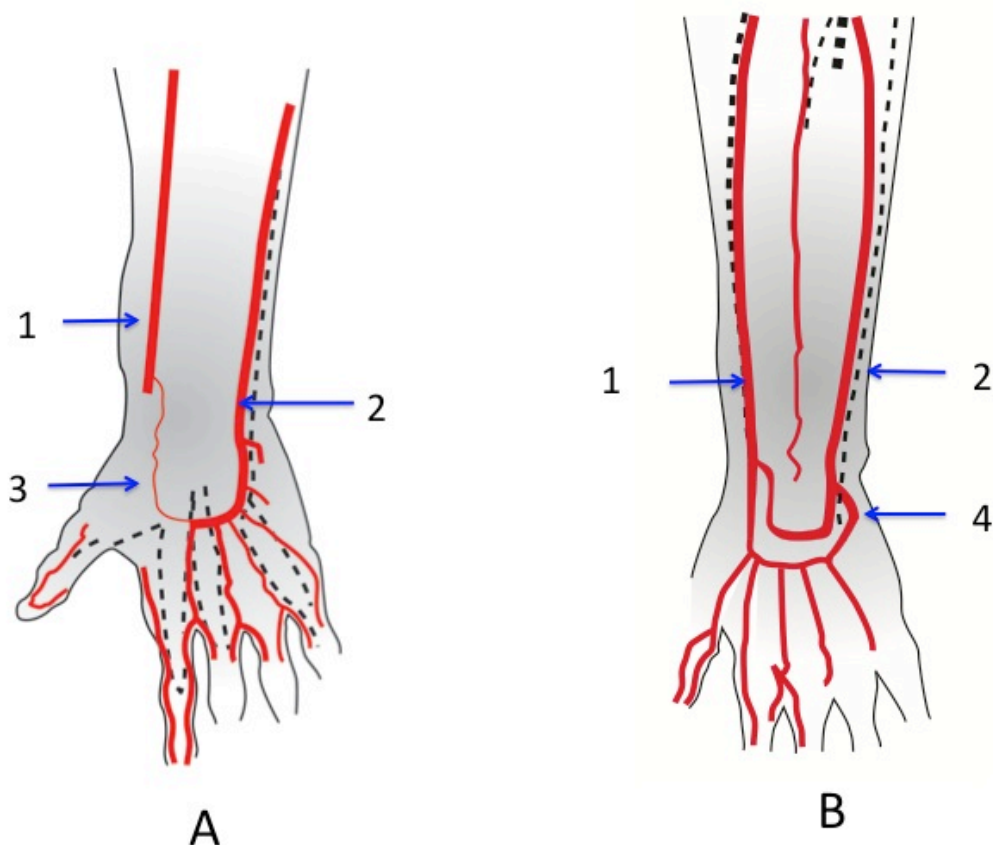


Figure 2: Palmar arterial arches of the hand. A: Superficial Palmar arch and B: Deep Palmar arch.

1. Radial artery, 2. Ulnar artery, 3. Superficial palmar branch of radial artery, 6. Deep branch of ulnar artery.

### Routes of arterial cannulation

The site chosen depends on collateral blood flow, accessibility, patient comfort, ease to care by nursing staff and ease to compress the artery in case of bleeding.

For these reasons, radial artery is most commonly chosen for performing cannulation.

The brachial, ulnar, femoral, dorsalis pedis and posterior tibial artery are occasionally used. In newborn, umbilical artery is preferred.

### Indications:

Aim of arterial cannulation is to allow continuous measurement of blood pressure and frequent blood gas sampling to determine the acid base status of the patient.

The main indications are:

- When continuous blood pressure measurement is needed as in critically ill patients and patients on inotropic support.

- Frequent arterial blood gas sampling is required for acid base determination.
- Conditions where there is inability to use noninvasive method; severe burns or there is inaccurate reading as in obesity.
- To guide the fluid management in critically ill patients. Haemodynamic parameters derived from arterial waveform are useful in fluid management of the patients.

**Contraindications:** The contraindication for arterial cannulation can be classified as absolute and relative.

*Absolute*

- Inadequate circulation to the extremity
- Raynauds syndrome
- Thromboangitis obliterans (Buerger disease)
- Full thickness burns or skin infection over insertion site

*Relative:*

- Severe coagulopathy
- Systemic anticoagulation
- Inadequate collateral flow from ulnar artery
- Atherosclerosis

**Complications:**

Bleeding

Arterial damage and thrombosis

Embolisation

Ischaemia of tissues distal to artery

Inadvertent injection of drugs

Infection

## **Preparation for the procedure**

### *Decision making*

Before performing the procedure, consider the need and anticipated duration of arterial cannulation. Inspect the site for infection, skin breakdown, presence of pulse and collateral circulation. Risks/ complications of inserting the arterial cannula versus benefits should be considered.

### *Consent*

The technique, advantages and complications of the procedure should be explained to the patient and informed consent is obtained and documented.

### *Allen's test*

Before attempting cannulation, Allen's test is performed to assess the collateral circulation in hand. Whilst cannulating the radial artery one should ensure that there is adequate collateral circulation through ulnar artery, in case thrombosis or complete occlusion of radial artery occurs. However the Allen's test has poor predictive value, hence clinical application varies.

### *Performing the Allen's test*

Elevate the hand and make fist for 30 seconds. This squeezes most of the blood out of fingers.

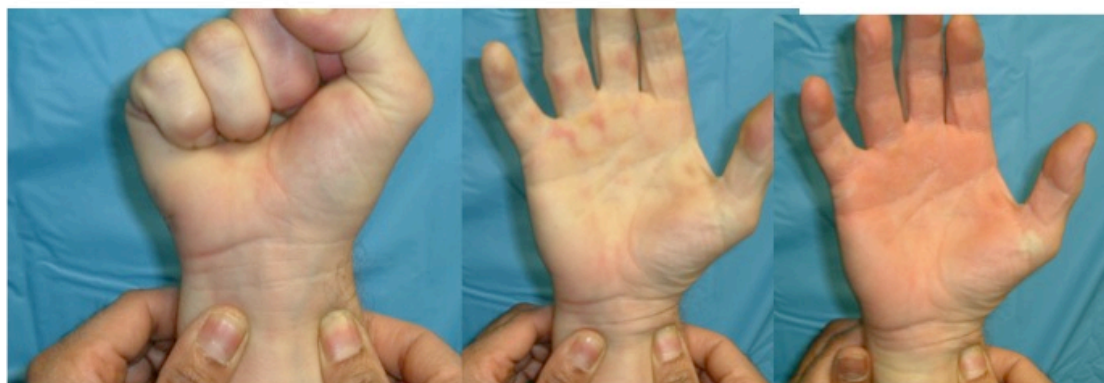Apply simultaneous pressure to occlude the radial and ulnar arteries at the wrist joint level.

Now ask the patient to release the fist. The hand would be blanched white due to absence of blood flow.

Release the ulnar artery, maintaining the occlusion of radial artery.

The perfusion of hand within 5-10 secs demonstrates adequacy of collateral flow from ulnar artery.

The above steps can be repeated to test the collateral circulation from radial artery, in case ulnar artery need to be cannulated.



A

B

C

*Figure 3: Allen's test, A: Both radial and ulnar arteries are occluded following a tight fist.*

*B: Fist is released but both arteries are occluded.*

*C: hand perfused following release of pressure on ulnar artery.*

#### *Equipment setup*

The equipments and other supplies needed for arterial cannulation are

Arterial cannula, local anaesthetic with syringe and 25 or 27 gauge needle, chlorhexidine, sterile gloves, sterile towel, adhesive tapes and clear semipermeable sterile dressing.

A high pressure tubing continuously flushed with normal saline, the saline bag should be maintained at constant pressure of 300 mm Hg

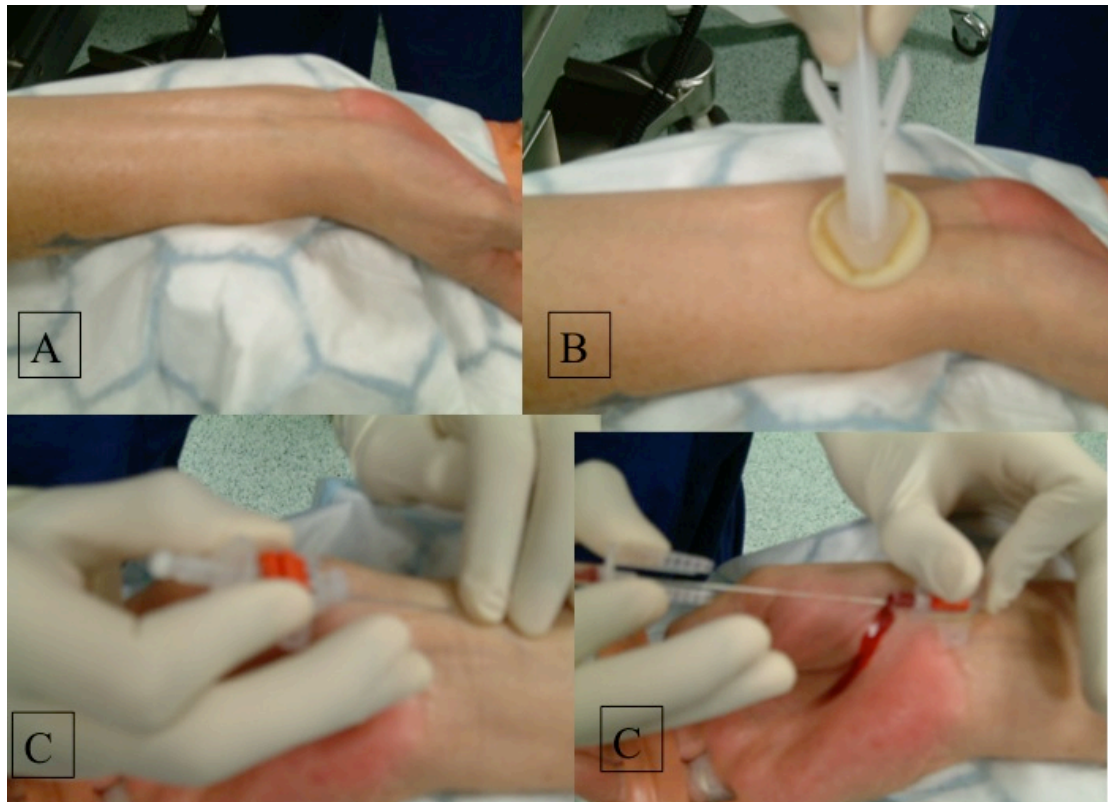
Transducer, amplifier and oscilloscope

#### *Technique of radial artery cannulation*

1. Position the patient to assess the site. In radial artery, wrist is extended and fixed to an arm board. Site is cleaned with chlorhexidine and draped.

2. Pulse is palpated with fingers or ultrasound is used to visualise the artery. Local anaesthetic is infiltrated in skin and subcutaneous tissue.

20 or 22 G Teflon arterial catheter over the needle is introduced and once pulsatile flow is noted, catheter is slipped into the vessel and needle is removed.



*Figure 4: Arm is positioned for radial artery cannulation(A), arm is cleaned with chlorhexidine solution, a 20 g teflon arterial cannula (catheter over the needle) is inserted by palpating the pulse (C). Needle is withdrawn and catheter is advanced once pulsatile flow is detected at the needle hub (D).*

Arterial cannulation can also be performed using seldinger technique in which needle is introduced and once pulsatile flow is obtained, guide wire is inserted and needle then removed. Catheter is advanced over the wire and wire then removed.

3. The catheter is then connected to transducer via fluid column with diaphragm acting as interface. The transducer is connected to amplifier and oscilloscope.

The flushing device allows 3-4 ml/hr saline to flush the cannula to prevent clotting and backflow through the catheter.

4. Within the pressure transducer, with each arterial pulsation, the saline column moves back and forth causing the diaphragm to move. This causes changes in the resistance and current flow through the wires of transducer which is then measured electronically converted and displayed as systolic, diastolic and mean arterial pressures.

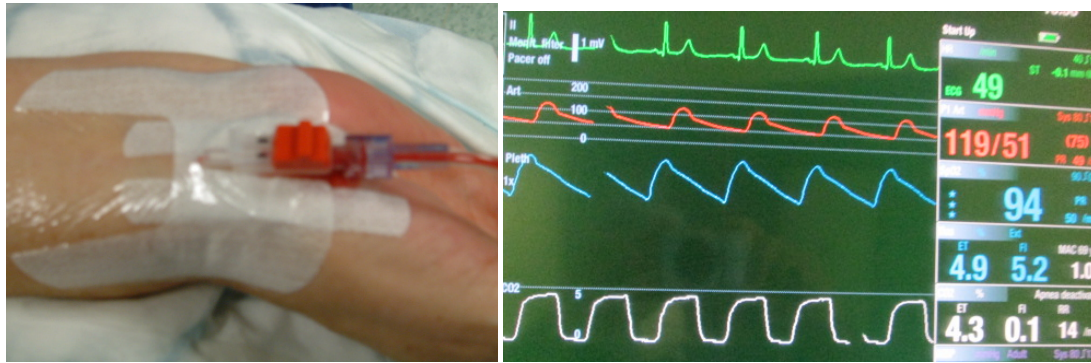


Figure 5: Transparent dressing is applied over the cannula. The cannula is connected to the transducer via high pressure tubing. Waveform and reading is viewed on the monitor.

### Information obtained from a arterial trace



Figure 6: A typical arterial trace from radial artery (A; systolic pressure, B; aortic valve closure notch, C; Diastolic pressure).

It measures the pulse rate, systolic, diastolic and mean blood pressure.

The slope of the systolic upstroke indicates the contractile state of the myocardium. The position of the aortic valve closure notch on the down stroke of the waveform reflects systemic vascular resistance. In presence of peripheral vasoconstriction, aortic valve closure notch is high and with vasodilatation it is lower down the curve.

### Post procedure care

Site should be regularly inspected for infection or any evidence of circulatory compromise e.g. cyanosis in fingertips.

The cannula should only be kept as long as it is indicated and removed if it is not needed.

### **Further reading**

Taylor L Sawyer, DO, MEd, FAAP, FACOP; Radial artery cannulation.  
<http://emedicine.medscape.com/>

<http://omicsonline.org/radial-artery-cannulation-a-review-article-2155-6148.1000209.pdf>



## Chapter 4

### Nasogastric Tube insertion

Dr Anuji Amarasekara

Gastric access via the nasal passage is a common procedure that is used for diagnostic and therapeutic purposes. Enteral feeding via nasogastric (NG) tube

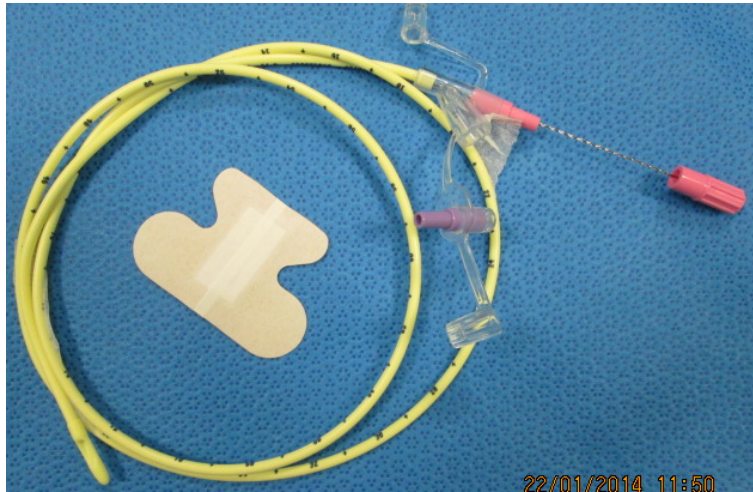
is a standard method used to restore or preserve nutrition. The earliest description of enteral feeding was described 3500 years ago in ancient Egyptians and Greeks. They mainly used enemas to infuse nutrients to preserve health and to treat diarrhoea. During that time rectal feeding was thought to be the preferred route due to difficulty in accessing the upper gastro intestinal (GI) tract. Subsequently feeding into upper GI tract was introduced in the 12th century.

### **Nasogastric Tubes**

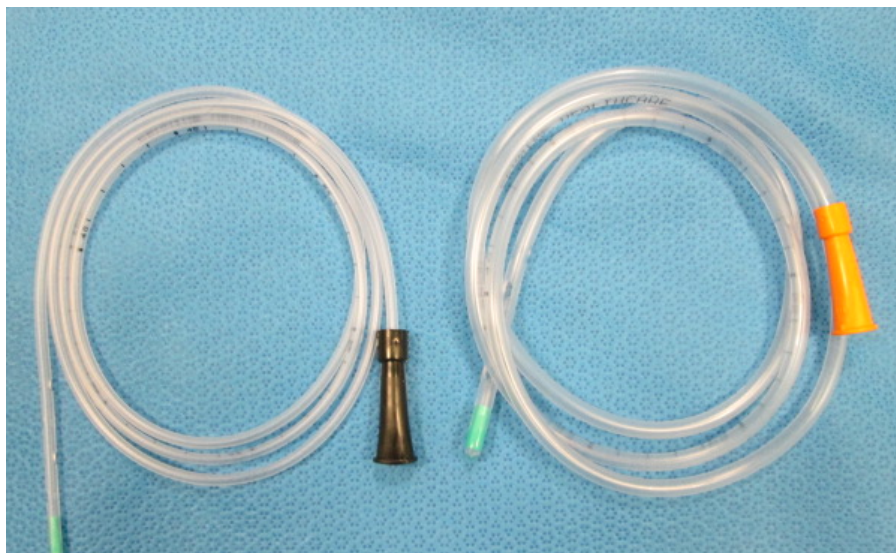
Nasogastric intubation generally requires a narrow tube, as it has to pass through the nasal cavity. A wide bore feeding tube is used if drainage is needed; otherwise a fine bore tube is inserted. The tubes are generally made of polyurethane or silicone as this can withstand the gastric acidity well. These can be kept in situ up to 6 weeks whereas the polyvinyl chloride (PVC) tubes can be kept for 2 weeks. If long term enteral feeding is needed a percutaneous endoscopic gastrostomy (PEG) is preferred.

### **Available Products**

**Ryle's tube:** Ryle's tube is a commonly used type of NG tube, manufactured from non-toxic, non-irritant material. The distal end has a corrosion resistant stainless steel ball sealed into the tube. This helps in assisting the passage of tube into the stomach. There are four lateral eyes that help in efficient aspiration and food administration. The tube has markings at 50, 60 and 70cm from the tip for accurate placement. The size of the tube varies from 8 FG to 24 FG and they are colour coded accordingly. The NG tube is radio opaque throughout the length, hence it is easily visible on X-ray.



*Figure 1: A fine bore feeding tube (note the guide wire). It is inserted with guide wire in situ. A chest must be performed after insertion to confirm the correct position. After confirming the correct placement, the guide wire is removed.*



*Figure 2: Nasogastric tubes of different sizes: 10 French gauge size (colour coded as black at the proximal end and 16 French gauge (colour coded as orange at the proximal end).*

### **Applied Anatomy:**

Nasopharynx extends superiorly from the nares to the soft palate inferiorly. The posterior oropharynx begins below the soft palate and extends inferiorly to the glottis and the oesophageal opening. Oesophagus is a tubular conduit between oropharynx and stomach.

The NG tube is inserted into the nostril aiming horizontally and posteriorly along the floor of the nasal cavity. Once the tube has passed the soft palate and entered the oropharynx, loss of resistance is felt. At this stage a conscious patient may gag. The marking on the NG tube will assist in judging the position of the tip of the tube. In an adult the distance from the nostril (external nares) to cardiac orifice of the stomach is about 44 cm and from cardiac orifice to the pylorus of stomach about 12-14 cm. Certain pathology may impede the passage of nasogastric tube such as a deviated nasal septum, oesophageal narrowing at the beginning of the oesophagus behind the cricoid cartilage and the point where the oesophagus enters the stomach.

### **Indications for insertion of NG tube:**

Can be broadly divided into diagnostic and therapeutic

Diagnostic:

- Check the quantity in upper gastrointestinal bleed
- Aspiration of gastric fluid contents
- Administration of radiographic contrast to GI tract

Therapeutic

- Gastric decompression
- Relief of symptoms in small bowel obstruction
- Lavage of gastric contents after ingestion of toxic substances
- Administration of medication
- Enteral nutrition
- Bowel irrigation
- Treatment of paralytic ileus
- Prevent aspiration and vomiting

### **Contraindications:**

Further subdivided into absolute and relative contraindication

Absolute Contraindications

- Severe mid face trauma (cribriform plate disruption) due to the possibility of insertion of tube intra-cranially
- Recent nasal surgery

#### Relative contraindications

- Oesophageal varices or strictures
- Clotting abnormalities
- Alkaline ingestion
- Recent banding or cautery of oesophageal varices
- Base of skull fractures

### **Complications**

#### **Thoracic complications**

- Patient discomfort: generous lubrication and gentle technique will reduce discomfort
- Epistaxis
- Bronchial placement leading to pneumonia atelectasis and lung abscess
- Bronchial perforation and pleural cavity penetration
- Empyema and sepsis
- Pleural knotted tube
- Pulmonary haemorrhage
- Intravascular penetration
- Oesophageal perforation
- Atelectasis from tracheal placement with suction applied
- Intrapulmonary administration of drug and feeds

#### **Non Thoracic complications**

- Tube knotting and impaction in the posterior nasopharynx
- Tube double backing and kinking
- Tube obstruction and rupture with kinking
- Tube breakage
- Enteral perforation

- Intracranial entry
- Hypertension and tachycardia depending on depth of sedation
- Sub mucosal dissection
- Glottic injury
- Vocal cord paralysis (nasogastric tube syndrome)(Sofferman et al., 1990)
- Disfiguring scars at the anterior nares due to pressure and erosion from the NG tube

### **Equipment needed for insertion of Nasogastric tube**

Nasogastric tube of selected size

Viscous Lidocaine 2%

10 ml Syringe

Glass of water with a straw

Water based lubricant

60 ml Toomey syringe

Adhesive tape or nasal dressing to fix the NG tube

Emesis basin or plastic bag

Wall suction set to low intermittent suction

Suction tubing and container

### **Insertion of Nasogastric tube in an awake patient:**

#### *Decision-making and consent*

Before a decision is made to insert a NG tube an assessment should be undertaken ensure that nasogastric feeding is appropriate for the patient and rationale for the decision should be recorded in the notes. The procedure, risk, benefits, complications and alternatives should be explained to the patient.

Patient's nostrils should be examined for any septal deviation.

#### *Insertion of NG tube*

Position the patient sat upright with the neck slightly flexed

In adult patients 10 ml of viscous lignocaine gel 2% is instilled into the more patent nostril and request the patient to sniff it up to anaesthetise the nasal and the oral mucosa. In paediatric patients the dose should not exceed 4mg/kg of Lignocaine. Wait for 5-10 minutes to anaesthetise the mucosa.

Length of the tube to be inserted can be measured by measuring the length from the tip of the nose, around the ear down to just below the costal margin.

Lubricate the end of the nasogastric tube. The nasogastric tube should then be gently inserted along the floor of the nose directly perpendicular to the patient's head until it reaches the back of the nasopharynx.

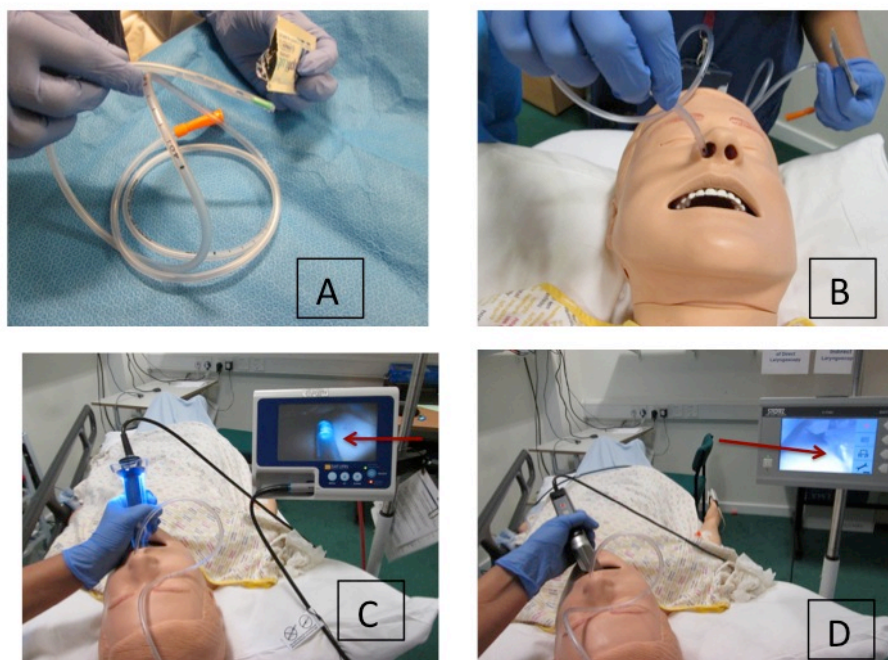
At this time ask the patient to swallow some water to facilitate the progress of the nasogastric tube. Continue to advance the nasogastric tube until previously determined length is achieved.

If the patient experience any respiratory discomfort or is unable to speak the nasogastric tube should be immediately withdrawn.

The nasogastric tube should then be taped securely to avoid displacement.

### **Insertion in anaesthetised or sedated patients**

Insertion of a NG tube in an anaesthetised or sedated patient can be most challenging procedure. If the patient is sedated and paralysed, place 2-3 fingers through patient's mouth into the oropharynx and guide the nasogastric tube into the hypopharynx. Lifting the thyroid cartilage anterior and upward might facilitate the entry of the nasogastric tube into the proximal oesophagus.



*Figure 3: Insertion of NG tube in an anaesthetised patient. A; Lubricating the tip of the NG tube using water based lubricant. B; Inserting the NG tube along the floor of*

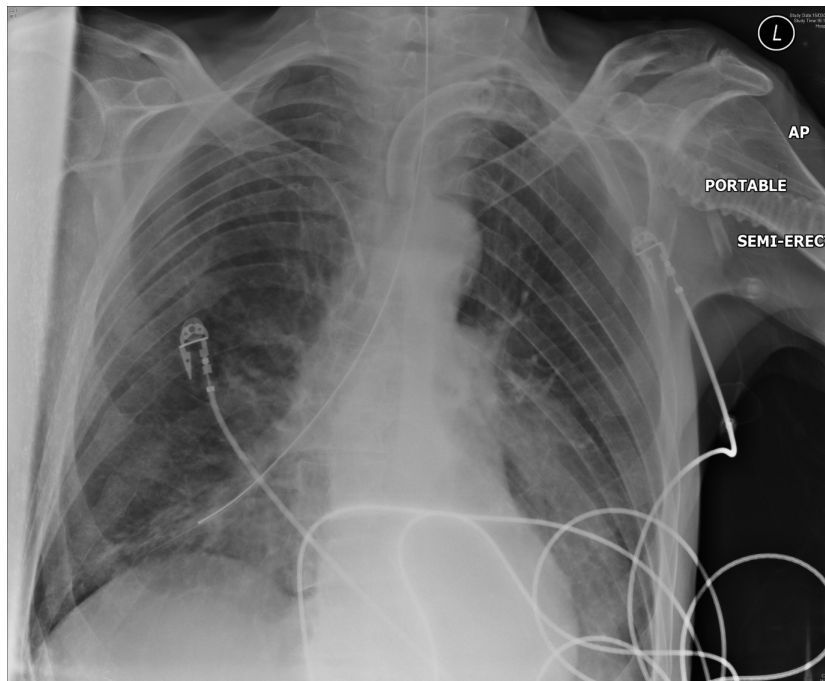
*Nose. C; Using Glidescope videolaryngoscope to visualise the tip of the tube (arrow).  
D; Using the C-MAC videolaryngoscope to visualise the tip of the tube (arrow)*

Using direct laryngoscopy or video laryngoscopy will aid insertion of nasogastric tube by direct visualization of the tip of the tube in sedated and paralysed patients.

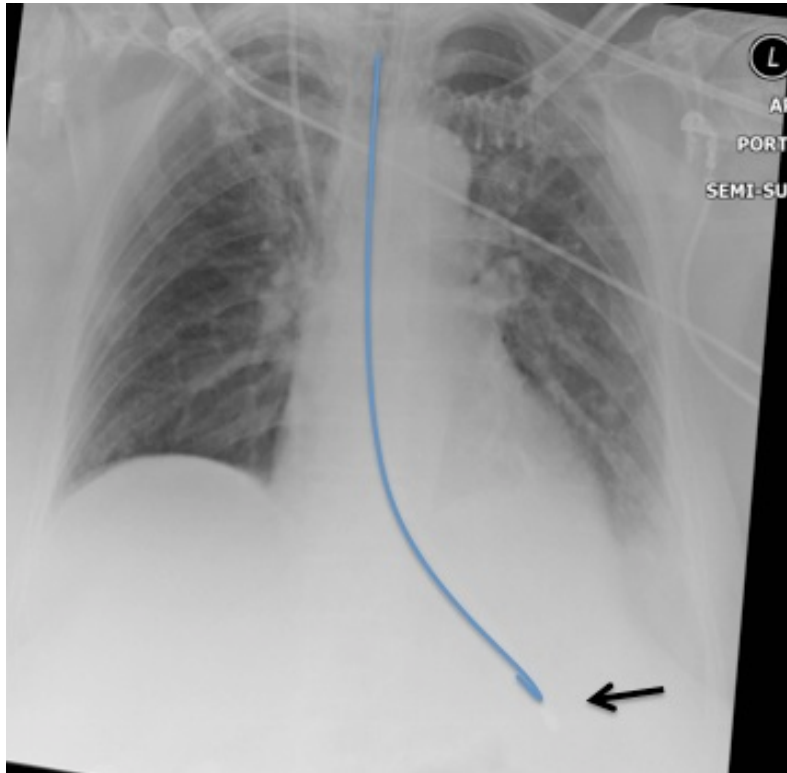
Freezing the NG tube was shown to increase the success rate for insertion in anaesthetised patients.

There are several techniques have been described to improve success rate of NG tube placement in an anaesthetised patient. These include use of ureteral or angiography guide wire as a stylet, use of a slit endotracheal tube as conduit, head flexion and lateral neck pressure and outward and rightward pull on the cricoid cartilage

Alternatively, indirect vision using videolaryngoscopes such as Glidescope can used to guide the NG tube.



*Figure 4: Chest X Ray illustrating nasogastric tube mal-positioned in the tracheo-bronchial tree.*



*Figure 5: Chest X Ray illustrating nasogastric tube in the correct position (arrow)*

### **Checking the placement of the nasogastric tube**

Correct position should be confirmed

- Immediately after initial placement
- Before each feed
- Following vomiting , coughing or if there is decrease in oxygen saturation
- If tube is accidently dislodged or if the patient complains of discomfort

### **How to check**

There are many methods to check whether the NG tube is in place. Some methods are unreliable and not recommended by the NPSA.

### **Unreliable methods**

- Visual inspection of aspirate – findings indicate that the location of only 50% of feeding tubes were correctly identified using this method.
- Auscultation test/ whoosh test (listening for bubbling sound after air entry )



This is an unreliable method of differentiating between gastric and respiratory placement and is not recommended by the NPSA

- Testing the acidity and alkalinity using blue litmus paper as blue litmus paper is not sensitive enough to distinguish between gastric and bronchial secretion

#### **Reliable methods (NPSA 2005 guidelines)**

- First line method – pH Paper: the pH should be between 1-5.5 as the safe range.
- Second Line method – X-ray confirmation: X-ray is used as a second line test only when aspirate cannot be obtained or pH indicator paper has failed to confirm the location of the nasogastric tube

#### **Post Procedure care**

The NG tube is generally placed on either suction or gravity.

Nasogastric tube should be checked

- Following initial insertion
- Before administering each feed
- Before giving medicine
- At least once daily during continues feed
- Following episode of coughing, retching or vomiting

Nothing should be administered through the NG tube until correct placement has been confirmed and documented.

#### **References**

1. Chernoff R (2006). An overview of tube feeding: from ancient times to the future. *Nutr Clin Pract*, 21, 408-10.
2. Pillai JB, Vegas A, Brister S (2005). Thoracic complications of nasogastric tube: review of safe practice. *Interact Cardiovasc Thorac Surg*, 4, 429-33.
3. Sofferman R A, Haisch C E, Kirchner J A, Hardin N J (1990). The nasogastric tube syndrome. *Laryngoscope*, 100, 962-8.
4. Agha R, Siddiqui M R (2011). Pneumothorax after nasogastric tube insertion. *JRSM Short Rep*, 2, 28.

5. Appukutty J, Shroff P P (2009). Nasogastric tube insertion using different techniques in anesthetized patients: a prospective, randomized study. *Anesth Analg*, 109, 832-5.
6. Chun D H, Kim NY, Shin Y S, Kim S H (2009). A randomized, clinical trial of frozen versus standard nasogastric tube placement. *World J Surg*, 33, 1789-92.
7. Gharib A M, Stern E J, Sherbin V L, Rohrmann C A (1996) Nasogastric and feeding tubes. The importance of proper placement. *Postgrad Med*, 99, 165-8, 174-6.
8. Lai H Y, Wang P K, Yang Y L, Lai J, Chen T Y (2006). Facilitated insertion of a nasogastric tube in tracheal intubated patients using the GlideScope. *Br J Anaesth*, 97, 749-50.

